

Case Report

Drug-Induced Fanconi Syndrome in a Patient with Breast Cancer: A Case Report

Fumi Saito^{1)*} Tadatoshi Osaku¹⁾ Genki Sato²⁾
 Makoto Sumazaki¹⁾ Yosuke Sasaki³⁾ Sho Kijima³⁾
 Yoshihisa Urita³⁾ and Hideaki Ogata¹⁾

¹⁾Division of Breast and Endocrine Surgery, Department of Surgery,
 Toho University School of Medicine, Tokyo, Japan

²⁾Division of Diabetes, Metabolism and Endocrinology, Department of Medicine,
 Toho University School of Medicine, Tokyo, Japan

³⁾Department of General Medicine and Emergency Care, Toho University School of Medicine, Tokyo, Japan

ABSTRACT: Fanconi syndrome (FS) is a rare disease characterized by a dysfunction of the proximal renal tubules. Drug-induced FS may be neglected or misdiagnosed, and most reported cases have occurred due to alkylating agents and platinum compounds. We encountered drug-induced FS in a patient with breast cancer using zoledronate. A 58-year-old woman underwent mastectomy for breast cancer at age 54. Two years later, bone metastases were detected and treated using a combination therapy of anastrozole and zoledronate. After 17 months, everolimus, exemestane, and zoledronate were prescribed. Then, she experienced hypocalcemia and proximal renal tubular dysfunction. FS induced by zoledronate was diagnosed, and zoledronate was immediately discontinued. This resulted in immediate and sustained improvement in renal function. In the past, three cases of zoledronate-induced FS were reported. All patients were prescribed zoledronate in combination with molecularly targeted drugs. Close monitoring of proximal tubular function is recommended for such patients.

Toho J Med 4 (4): 146–151, 2018

KEYWORDS: fanconi syndrome, zoledronate, breast cancer

Background

Fanconi syndrome (FS) is a rare disorder characterized by inadequate reabsorption in the proximal tubules (PTs) of the kidney due to various causes, including hereditary conditions such as cystinosis, mitochondrial cytopathy, tyrosinemia, fructose intolerance, galactosemia, Wilson's disease, Dent's disease, Lowe syndrome, and several therapeutic drugs. The most frequently implicated drugs are

cisplatin, ifosfamide, tenofovir, sodium valproate, and aminoglycoside.¹⁾

Zoledronate is a nitrogen-containing bisphosphonate with potent inhibitory effects on bone resorption in patients with bone metastases from solid tumors. It is excreted by the kidneys; thus, its dose should be monitored carefully in patients with renal dysfunction. Nephrotoxicity induced by zoledronate has been reported and considered to be mainly due to tubular necrosis. Cases of

1, 2, 3) 6-11-1 Omorinishi, Ota, Tokyo 143-8541, Japan

*Corresponding Author: tel: +81-3-3762-4151

e-mail: fumi.saitou@med.toho-u.ac.jp

DOI: 10.14994/tohojmed.2018-006

Received Apr. 13, 2018; Accepted June 28, 2018

Toho Journal of Medicine 4 (4), Dec. 1, 2018.

ISSN 2189-1990, CODEN: TJMOA2

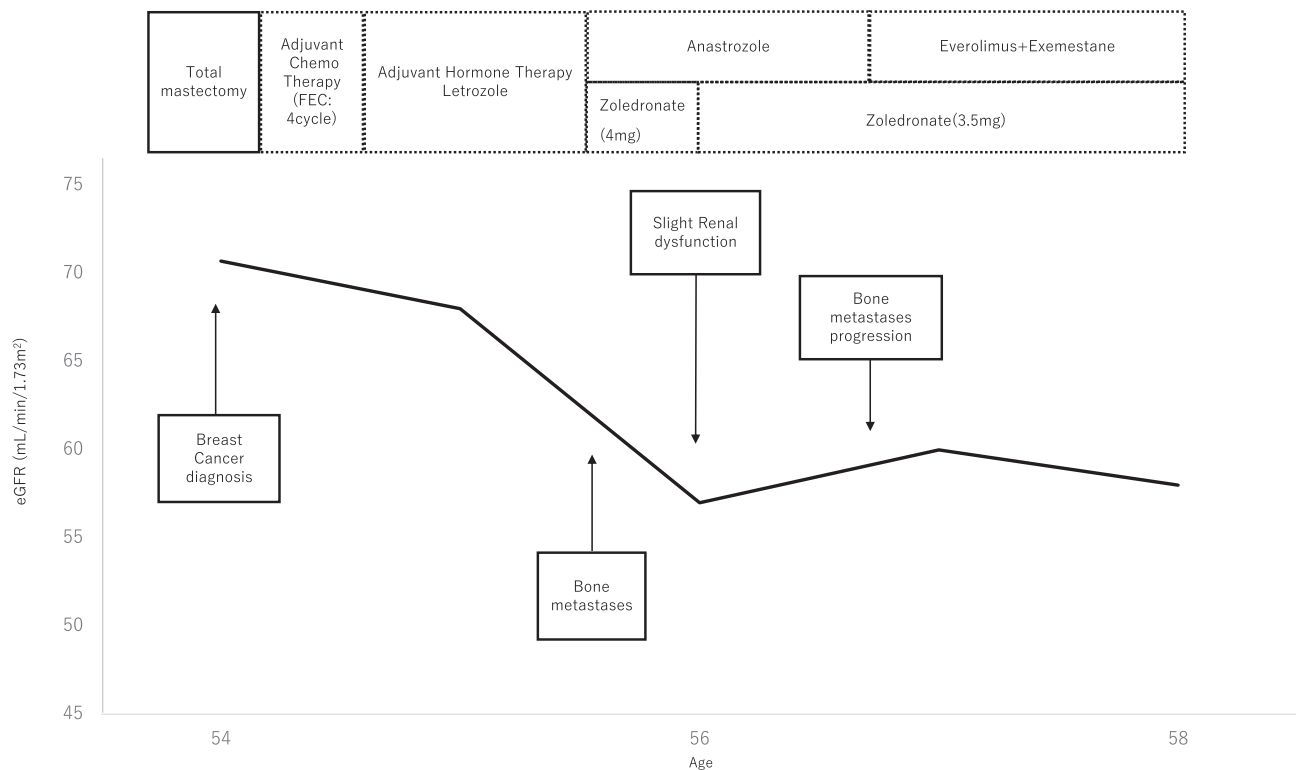


Fig. 1 Treatment course for breast cancer

FEC: fluorouracil, epirubicin and cyclophosphamide (5- fluorouracil at 500 mg/m², epirubicin at 100 mg/m², and cyclophosphamide at 500 mg/m² on day 1, repeated every 21 days)

zoledronate-induced FS are rare. To the best of our knowledge, only three reports have identified zoledronate-induced FS in Japan.²⁻⁴⁾ Further, there were a few reports in a foreign country.

We encountered a case of drug-induced FS in a patient to whom zoledronate had been prescribed for bone metastases due to breast cancer.

This case report was approved by the ethics committee of Toho University Omori Medical Center, with number 26-256.

Case Presentation

The patient was a 58-year-old woman who had undergone left total mastectomy for breast cancer when she was 54 years old. No family history of neurological disease or renal disorder was evident, and the patient had no medication allergies. The pathological diagnosis was T2N0 M0 stage II, according to the International Union Against Cancer 7th TNM classification for breast cancer. Her hormone receptor status was positive for both estrogen and progesterone receptors and negative for human epidermal growth factor receptor 2 protein. This case was classified as Luminal A. Postoperatively, the patient received 4 cy-

cles of 5-fluorouracil, epirubicin, and cyclophosphamide (at 500, 100, and 500 mg/m², respectively, on day 1, repeated every 21 days) as adjuvant chemotherapy.

After these therapies, letrozole was prescribed to the patient as an adjuvant hormone therapy. Letrozole is classified as an aromatase inhibitor (AI).

Two years later, multiple bone metastases (in the thoracic vertebra, rib, and ilium) were identified. The patient received intravenous zoledronate at a dose of 4 mg infused over 15 min administered every 4 weeks, and anastrozole (which is classified as an AI) was prescribed. Two months later, slight renal dysfunction was detected; thus, the zoledronate dose was reduced to 3.5 mg. No clear deterioration of renal function was seen after this dose reduction. The patient's treatment course for breast cancer is shown in Fig. 1.

Seventeen months after the first recurrence, progression of bone metastases was identified, and everolimus, exemestane (which is an AI), and zoledronate were prescribed. Two weeks after starting these therapies, glucosuria was clearly identified, although the patient had no medical history of diabetes. A few days later, she presented to our outpatient clinic complaining of appetite loss,

Table 1 Laboratory Examination and Urinary analysis

Blood examination				Urinalysis	
WBC	3.2×10^3 / μ L	Alb	3.1 g/dL	pH	7.0
Hb	10.6 g/dL	T-bil	0.7 mg/dL	protein	2+
Ht	28.80 %	BUN	6 mg/dL	glucose	3+
Plt	173×10^3 /L	Cr	1.36 mg/dL	blood	2+
PT	10.5 sec	UA	0.8 mg/dL	Na	92 mM
PT-INR	0.9	eGFR	31.9 mL/min/1.73 m ²	K	18.3 mM
APTT	27.0 sec	Glucose	120 mg/dL	Cl	85 mM
Na	139 mM	HbA1c (NGSP)	5.60 %	Cr	66 mM
K	2.7 mM	Blood gas analysis (room air)		albumin	87.3 μ g/mL
Cl	109 mM	pH	7.376	CCR	31 mL/min
Ca	8.3 mg/dL	pCO ₂	30 mmHg	β 2MG	91805 μ g/L
IP	0.7 mg/dL	pO ₂	79.0 mmHg	FE _K	18.10 %
CRP	0.7 mg/dL	HCO ₃ ⁻	17.2 mmol/L	TmP/GFR	0.79 mg/dL
AST	40 U/L	BE	-6.6 mmol/L		
ALT	20 U/L	Anion Gap	8 mmol/L		
LDH	416 U/L				
ALP	231 U/L				
TP	6.9 g/dl				

HbA1c was estimated as the National Glycohemoglobin Standardization Program (NGSP) equivalent value, which was calculated as HbAc (NGSP) (%) = HbA1c (Japan Diabetes Society) (%) + 0.4%.

β 2MB; β 2-microglobulin; FE_K; fractional excretion of K; TmP/GFR: tubular maximal transport of phosphatase reabsorption to the glomerular filtration rate transport.

severe fatigue, and severe hypokalemia (plasma potassium: 2.7 mEq/L). On admission, the patient's height was 145 cm; body weight, 36.5 kg; body mass index, 17.2 kg/m²; blood pressure, 118/87 mmHg; heart rate, 98 beats/min and regular; body temperature, 36.7°C; and peripheral oxygen saturation, 98%.

Laboratory data (Table 1) showed renal dysfunction, as evidenced by a creatinine clearance rate of 31 mL/min; blood urea nitrogen, 6 mg/dL; serum creatinine, 1.36 mg/dL; and estimated glomerular filtration rate, 31.9 mL/min/1.73 m². Blood electrolytes showed hypokalemia, hypocalcemia, hypophosphatemia, and hypouricemia. Arterial blood gas analysis showed metabolic acidosis. The bicarbonate concentration was decreased to 17.2 mmol/L, but respiratory compensation normalized the pH. The anion gap and gastrointestinal functions were normal, indicating that the cause of the metabolic acidosis was renal tubular acidosis. The ratio of tubular maximum reabsorption of phosphate to glomerular filtration rate was 0.79 mg/dL. Based on these findings, hypokalemia with renal tubular acidosis was considered as the diagnosis. A urinary examination showed urinary phosphorus, glucosuria, albuminuria, β 2-microglobulinuria, and generalized aminoaciduria. Despite the glucosuria, the patient's fasting blood glucose

was 120 mg/dL (normal range, 73-109 mg/dL) and hemoglobin A1c was within the normal range. The cause of the glucosuria was thus considered to be renal diabetes.

A normal anion gap, metabolic acidosis, hypokalemia, hypophosphatemia, and glucosuria indicated proximal renal tubular acidosis, which is characteristic of FS.

In this case, FS was most probably drug-induced, because of its adult onset and lack of other coexisting diseases.

After reaching this diagnosis, zoledronate, everolimus, and exemestane were immediately discontinued. The patient was aggressively rehydrated with intravenous fluids. She required fluid replacement with 40 mEq potassium chloride for the first 5 days intravenously, and with 24 mEq potassium chloride orally for the subsequent 7 days. Phosphorus was replaced in the same way. The treatment course of the patient is shown in Fig. 2.

Four weeks after starting treatment, the serum phosphorus level had normalized, and urine analysis revealed a pH of 6.0, with mild proteinuria and glucosuria. The trend of the laboratory data is shown in Table 2.

Discussion

FS is a disease characterized by the dysfunction of renal

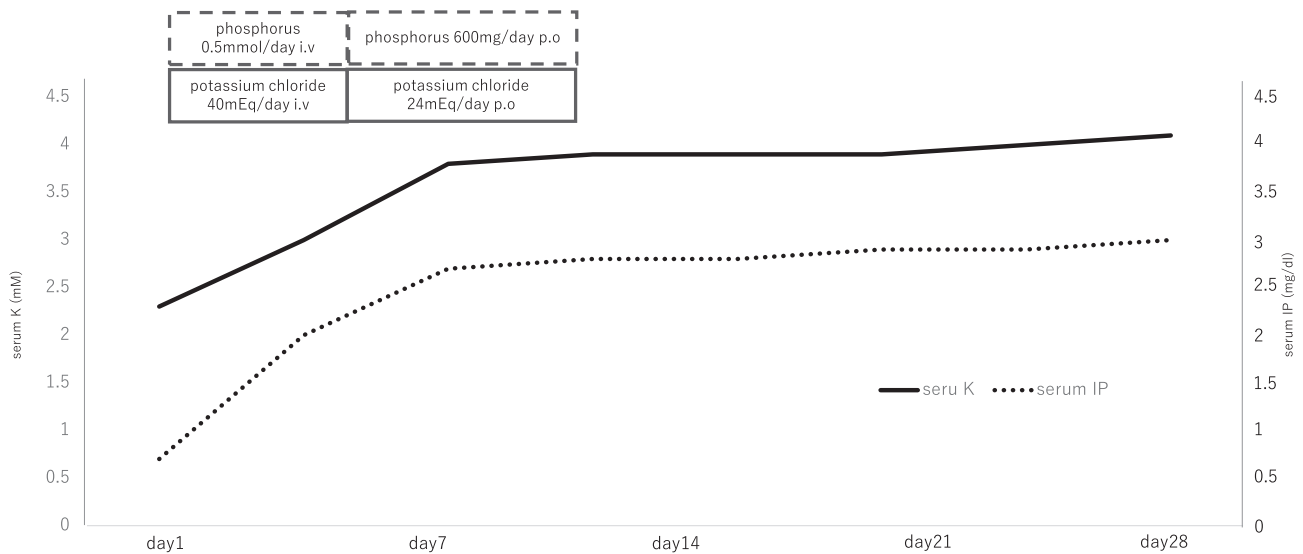


Fig. 2 Trend of Laboratory data and Treatment Course of Fanconi Syndrome

Table 2 Trend of laboratory data of the patient

		Base line *	On hospital admission			After discharge
		Day	1	3	7	28
Serum	K (mM)	3.7	2.3	2.7	3.8	4.1
	IP (mg/dl)	3.7	0.7	0.7	2.7	3.0
	Ca (mg/dl)	9.3	8.5	8.3	9.3	9.8
Urinalysis	eGFR	59.9	27.1	31.9	38.1	39.1
	protein	(-)	2+	2+	N/A	+
	glucose	(-)	3+	3+	N/A	(±)
	β2MG	N/A	N/A	91805	N/A	10956

*: baseline is the date before everolimus was administered.

N/A: not applicable; β2MB: β2-microglobulin.

Table 3 Risk factors for drug-induced renal FS

Drug dose and duration of therapy
Pre-existing renal impairment
Reduced renal mass (e.g., previous nephrectomy)
Older age or very young
Drug interactions
Low body weight
Volume depletion (e.g., diarrhoea and vomiting)
Underlying pharmacogenetic factors

PTs resulting from various pathogenic events. This condition was first reported by Lignac in 1924 and further defined by Fanconi in 1936 in children presenting with rickets, growth retardation, and glucosuria.⁵⁾

Several drugs can induce secondary FS, such as tenofovir, ifosfamide, aminoglycoside, and fumaric acid es-

ters.^{1,6)} In this case, exemestane was excluded as a possible causative drug, because other AIs (letrozole and anastrozole) had already been prescribed without the onset of renal dysfunction. No reports have described everolimus-induced FS, whereas three reports have noted zoledronate-induced FS. In this case, zoledronate was the most probable causative drug, but we could not exclude the possibility of everolimus-induced FS. We therefore discontinued both drugs immediately.

Balak et al. reported drug-induced FS associated with fumaric acid ester treatment for psoriasis. The most commonly reported presenting symptoms for FS in this article were generalized weakness (27%), myalgia (27%), and arthralgia (27%).⁶⁾ However, these symptoms are neither particularly frequent nor specific to FS.

Other complications of FS include fatigue and muscle

Table 4 Case reports of FS induced by zoledronate

	Torimoto et al ³⁾	Yoshinami et al ²⁾	Okagawa et al ⁴⁾	this case
age	54y	61y	sixties	58y
sex	female	female	female	female
primary disease	breast cancer	breast cancer	colon cancer	breast cancer
reason for zoledronate prescribed	bone metastases	malignancy associated hypercalcemia	bone metastases	bone metastases
area of metastases	bone, liver	liver	bone	bone
combination therapy	Trasuzumub	Trasuzumub + Paclitaxel	mFOLFOX + Bevacizumub	Everolimus + Anastrozole
administration dose	4 mg	4 mg	4 mg	4 → 3.5 mg
time	N/A	over 15 min	over 15 min	over 15 min
interval	monthly	weekly	monthly	monthly
total amount	48 mg/12monthes	32 mg/8weeks	68 mg/17monthes	60.5 mg/17monthes

N/A: not applicable.

soreness, difficulty in walking, and spontaneous fracture. As a result, doctors may tend to neglect the detection and diagnosis of drug-induced FS and many cases may be misdiagnosed. In particular, diagnosis is difficult for patients with metastatic bone tumors due to other malignant diseases, such as breast and colorectal cancers, because bone pain is already present.

Laboratory tests typically show low serum levels of phosphatase and uric acid, along with PT acidosis. The diagnosis of FS was based on laboratory test results.

Is renal biopsy needed to diagnose FS? In this case, we did not perform renal biopsy, because Hall et al. reported no histological features specific to FS. However, the presence of dysmorphic and swollen mitochondria in PTs is a common finding on electron microscopy in drug-induced FS.^{7,8)}

The risk factors for drug-induced renal FS are shown in Table 3.^{1,8,9)} In this case, loss in body weight and dehydration from appetite loss as a side effect of breast cancer treatments, such as chemotherapy, led to the development of FS. Patients with a malignant disease, older age, body weight loss from appetite loss, diarrhea, and vomiting as side effects from the treatment of malignant disease are at an increased risk of FS. Thus, physicians need to be cautious with such patients.

If a patient develops drug-induced FS while taking a nephrotoxic drug, its administration should be suspended immediately. However, if no alternative drugs are available, should treatment be abandoned?

Hall et al. suggested that discontinuation is not feasible. For example, if no alternative drug is available and the clinical situation is life threatening, a dose reduction should

be considered.¹⁾ However, Okagawa et al. reported that after the diagnosis of zoledronate-induced FS, denosumab was administered to treat bone metastases, without causing any decline in renal function.⁴⁾

Table 4 shows reports of zoledronate-induced FS. Okagawa et al. reported no direct link between administration dosage and FS development.⁴⁾ Rosen et al. reported that the frequency of renal dysfunction depended on the duration of administration and dosage.¹⁰⁾ Therefore, the relationship between administration dosage and FS development remains unclear. Herlitz et al. reported zoledronate-induced FS with concomitant trastuzumab use.⁷⁾ In a patient using a combination therapy of zoledronate and other drugs, clinical manifestations of tubular injury may not appear in the long term.⁷⁾ Therefore, they advocated exercising caution, especially with patients concomitantly receiving molecularly targeted drugs.³⁾

Conclusion

We have reported a case of FS induced by zoledronate use. Zoledronate was prescribed to the patient to treat a malignant disease and it warranted close monitoring of the PT function, at least at every administration, given her age and the concomitant use of molecularly targeted drugs.

Conflicts of interest: None declared.

References

- 1) Hall AM, Bass P, Unwin RJ. Drug-induced renal Fanconi syndrome. *QJM*. 2014; 107: 261-9.
- 2) Yoshinami T, Yagi T, Sakai D, Sugimoto N, Imamura F. A case of

- acquired Fanconi syndrome induced by zoledronic acid. *Intern Med.* 2011; 50: 1075-9.
- 3) Torimoto K, Okada Y, Arao T, Mori H, Tanaka Y. A case of zoledronate-induced tubulointerstitial nephritis with Fanconi syndrome. *Endocr J.* 2012; 59: 1051-6.
 - 4) Okagawa Y, Sato Y, Onuma H, Osuga T, Hayashi T, Sato T, et al. A case of Fanconi syndrome induced by zoledronic acid in a metastatic colorectal cancer patient. *Gan To Kagaku Ryoho.* 2015; 42: 867-70.
 - 5) Mathew G, Knaus SJ. Acquired Fanconi's syndrome associated with tenofovir therapy. *J Gen Intern Med.* 2006; 21: C3-5.
 - 6) Balak DM, Bavinck BJN, de Vries AP, Hartman J, Neumann HA, Zietse R, et al. Drug-induced Fanconi syndrome associated with fumaric acid esters treatment for psoriasis: a case series. *Clin Kidney J.* 2016; 9: 82-9.
 - 7) Herlitz LC, Mohan S, Stokes MB, Radhakrishnan J, D'Agati VD, Markowitz GS. Tenofovir nephrotoxicity: acute tubular necrosis with distinctive clinical, pathological, and mitochondrial abnormalities. *Kidney Int.* 2010; 78: 1171-7.
 - 8) Hall AM, Hendry BM, Nitsch D, Connolly JO. Tenofovir-associated kidney toxicity in HIV-infected patients: a review of the evidence. *Am J Kidney Dis.* 2011; 57: 773-80.
 - 9) Perazella MA, Moeckel GW. Nephrotoxicity from chemotherapeutic agents: clinical manifestations, pathobiology, and prevention/therapy. *Semin Nephrol.* 2010; 30: 570-81.
 - 10) Rosen LS, Gordon D, Kaminski M, Howell A, Belch A, Mackey J, et al. Zoledronic acid versus pamidronate in the treatment of skeletal metastases in patients with breast cancer or osteolytic lesions of multiple myeloma: a phase III, double-blind, comparative trial. *Cancer J.* 2001; 7: 377-87.

Toho Journal of Medicine. Toho Journal of Medicine is an Open Access journal distributed under the Creative Commons Attribution-NonCommercial-NoDerivatives 4.0 International License. To view the details of this license, please visit (<https://creativecommons.org/licenses/by-nc-nd/4.0/>).